

## Abstract

# DOES ONE-STAGE EXCHANGE WITH ANTIBACTERIAL COATING OF IMPLANTS PROVIDE SIMILAR RESULTS TO A TWO-STAGE PROCEDURE FOR THE TREATMENT OF PERI-PROSTHETIC JOINT INFECTION?

Gallazzi E., Capuano N., Scarponi S., Morelli I., Romanò C.L.

**Published Online:** 21 Feb 2018

 About

 Tools  Share

Infection remains among the first reasons for failure of joint prosthesis. Currently, the golden standard for treating prosthetic joint infections (PJIs) is two-stage revision. However, two-stage procedures have been reported to be associated with higher costs and possible higher morbidity and mortality, compared to one-stage. Furthermore, recent studies showed the ability of a fast-resorbable, antibacterial-loaded hydrogel coating to reduce surgical site infections after joint replacement, by preventing bacterial colonization of implants. Aim of this study was then to compare the infection recurrence rate after a one-stage, cementless exchange, performed with an antibacterial coated implant versus a standardized two-stage revision procedure.

In this two-center prospective study, 22 patients, candidate to revision surgery for PJI, were enrolled to undergo a one-stage revision surgery with cementless implants, coated intra-operatively with a fast-resorbable, antibiotic-loaded hyaluronan and poly-D,L-lactide based hydrogel coating ("Defensive Antibacterial Coating", DAC, Novagenit, Italy). DAC was reconstructed according to manufacturer indications and loaded with Vancomycin or Vancomycin + Meropenem, according to cultural examinations, and directly spread onto the implant before insertion. This prospective cohort was compared with a retrospective series of 22 consecutive patients, matched for age, sex, host type, site of surgery, that underwent a two stage procedure, using a preformed, antibiotic-loaded spacer (Tecres, Italy) and a cementless implant. The second surgery, for definitive implant placing, was performed only after CRP normalization and no clinical sign of infection. Clinical, laboratory and radiographic evaluation were performed at 3, 6 and 12 months, and every 6 months thereafter. Infection recurrence was defined by the presence of a sinus tract communicating with the joint, or at least two among the following criteria: clinical signs of infections; elevated CRP and ESR; elevated synovial fluid WBC count; elevated synovial fluid leukocyte esterase; a positive cultural examination from synovial fluid; radiographic signs of stem loosening.

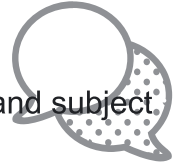The two groups did not differ significantly for age, sex, host type and site of surgery (18 knees and 4 hips, respectively). The DAC hydrogel was loaded intra-operatively, according to cultural examination, with vancomycin (14 patients) or vancomycin and meropenem (8 cases). At a mean follow-up of  $20.2 \pm 6.3$  months, 2 patients (9.1%) in the DAC group showed an infection recurrence, compared to 3 patients (13.6%) in the two-stage group. No adverse events associated with the use of DAC or radiographic loosening of the stem were observed at the latest follow-up months.

This is the first report on one-stage cementless revision surgery for PJI, performed with a fast-resorbable antibacterial hydrogel coating. Our data, although in a limited series of patients and at a relatively short follow-up, show similar infection recurrence rate after one-stage exchange with cementless, coated implants, compared to two-stage revision. These findings warrant further studies in the possible applications of antibacterial coating technologies to treat implant-related infections.

---

## Bone & Joint Publishing Comment Policy

We welcome relevant and respectful comments. All comments are moderated and subject to removal.



0 Comments

Bone & Joint Publishing

 Login ▾

 Recommend

 Share

Sort by Best ▾



Start the discussion...

LOG IN WITH

OR SIGN UP WITH DISQUS 

Name

Be the first to comment.

### ALSO ON BONE & JOINT PUBLISHING

#### To operate or not to operate, that is the question

2 comments • 11 days ago



**Bone & Joint** — AUTHORS' REPLY TO:  
Handoll et al Clarifications on the design and conduct of the PROFHER trial Michelle ...

#### A randomised controlled trial comparing skin closure in total knee arthroplasty in ...

1 comment • 14 days ago



**Bone & Joint** — Letter to the Editor Xi-Wei Liu, Attending doctor of Knee Surgery, Department of Knee Surgery, Honghui Hospital, Xi'an ...

#### Recurrence of frozen shoulder after manipulation under anaesthetic (MUA)

1 comment • 15 days ago






**Bone & Joint** — eLetter: Recurrence of frozen shoulder after manipulation under anaesthetic (MUA) – the results of repeating the ...

#### Five-year follow-up results of the PROFHER trial comparing operative and ...

3 comments • a month ago



**Bone & Joint** — Rometsch et al response to authors' reply: E Rometsch, Health Scientist, Project Manager, Medical Writing, AO ...

 Subscribe  Add Disqus to your site [Add Disqus](#) [Add](#)  Privacy



# Bone & Joint Publishing



The British Editorial Society of Bone & Joint Surgery, 22 Buckingham Street, London WC2N 6ET +44 (0) 20 7782 0010

[Terms and conditions](#)   [Privacy policy](#)   [Refunds policy](#)

© 2018 The British Editorial Society of Bone & Joint Surgery. Registered charity no: 209299.

Powered by [Atypon®](#) Literatum