


Defensive antibacterial coating in revision total hip arthroplasty: new concept and early experience

HIP International
2020, Vol. 30(1S) 7–11
© The Author(s) 2020
Article reuse guidelines:
sagepub.com/journals-permissions
DOI: 10.1177/1120700020917125
journals.sagepub.com/home/hpi


Massimo Franceschini¹, N Amir Sandiford², Vincenzo Cerbone¹,
Lucio Cappelli Toledo de Araujo^{3,4} and Daniel Kendoff⁴

Abstract

Background: Infections remains the most feared complication in total hip arthroplasty (THA). New strategies of PJI prevention includes coating of conventional implants. Defensive Antibacterial Coating (DAC), an antibacterial hydrogel coating made of hyaluronan, poly-D and L-lactide can protect biomaterials as an effective barrier at the time of implantation. In addition, it can be used with topical antibiotics to prevent early colonisation of the implant.

Scope: This manuscript describes the detailed function of the DAC in general as well as an analysis of its use in revision THA in a series of 28 patients in a short-term follow-up.

Its use in patients undergoing cementless re-implantation after 2-staged procedures in THA is described in detail within the manuscript.

Conclusion: DAC found to be effective in terms of infection control and safety in our patient cohort and has been expanded for cementless 1-staged revisions in PJI of the hip in our institution.

Keywords

Antibacterial coating, cost, infection, PJI, revision arthroplasty, total hip arthroplasty

Date received: 21 February 2020; accepted: 21 February 2020

Introduction

Total hip arthroplasty (THA) is 1 of the most successful operations in the history of orthopaedic surgery.¹ The incidence of joint replacement procedures is high, with over 1 million total hip and total knee replacement procedures each year in the United States.² In Europe approximately 1.5 million joint arthroplasties are performed annually.³ Infection is 1 of the most feared complications for THA.⁴ According to the National Joint Registry from United Kingdom, the top 5 most common indications for re-revision (in order of greatest frequency) were aseptic loosening, dislocation/subluxation, infection, pain and periprosthetic fracture.⁵ Despite the use of routine systemic antibiotic prophylaxis administration as well as improved surgical facilities and procedures, periprosthetic joint infection (PJI) is still among the major causes for failure of THA with an incidence according to registry data that is rising.^{5–8}

The World Health Organization (WHO) guidelines on the prevention of surgical site infection are valid for any country and suitable to local adaptations and take account

of the strength of available scientific evidence, the cost and resource implications, and patient values and preferences.⁹ With a new definition of prosthetic joint infection and an evidence-based diagnostic algorithm to guide diagnosis, the proper evaluation and subsequent treatment of PJI stands to improve even further in the near future.^{1,9,10}

The incidence of PJI following primary THA has remained relatively unchanged at 1–2% over the last decade however as the number of THA procedures increase, the number of cases of hip related PJI cases is likely to increase. Swedish registry showed that PJI is also a major

¹Istituto Ortopedico “G. Pini”, Milan, Italy

²Southland Hospital, Invercargill, New Zealand

³Regional Hospital of São José Dr. Homero M Gomes, São José, Santa Catarina, Brazil

⁴HELIOS Klinikum Buch, Berlin, Germany

Corresponding author:

Massimo Franceschini, Istituto Ortopedico Gaetano Pini, Piazza

Cardinal Ferrari 1, Milano, Lombardia 20122, Italy.

Email: massimo.franceschini@asst-pini-cto.it

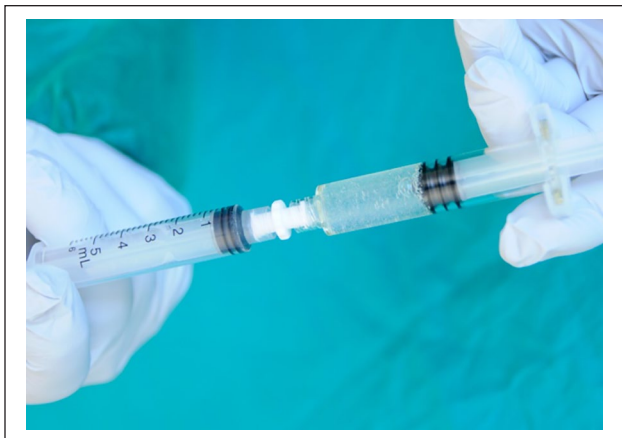

Figure 1. Mixture of DAC, water and antibiotic.

cause of failure in patients undergoing revision and re-revision THA.¹¹ In these populations the incidence is increasing. PJI are associated with an increase in both the incidence of morbidity and in mortality rate. Management of PJI is also associated with a significant economic burden and resource utilisation.¹² The hospital costs, related to the management of PJI, range from approximately from €20 000 to €60 000,^{13–15} while the long-term economic effect of post-surgical infection after joint arthroplasty has been calculated to exceed \$390 000 per case.^{15,16}

For the reasons discussed above, it remains crucial to evaluate new technologies and techniques to prevent PJIs. Several technologies have been introduced in last recent years. 1 possible strategy to prevent bacterial adhesion is the use of antibacterial local carriers or coatings that are not built into the device, but rather are applied during surgery. Their aim is to have direct or synergistic antibacterial/anti-adhesive activity.

When a biomaterial is implanted, a competition between the host and the bacteria occurs for surface colonisation. If bacterial adhesion to an implant occurs, immediate biofilm formation starts, making the bacteria extremely resistant to the host's defense mechanisms and antimicrobials.^{17,18}

Antibacterial coating is a relatively new possible treatment options regarding for PJI in the hip, just for uncemented THA.

1 such agent is the Defensive Antibacterial Coating (DAC, Adler Orthopedics, Italy) technology. It comprises an antibacterial hydrogel coating, composed by hyaluronan and poly-D, L-lactide and has shown promising early results, as reported by the inventing group of this agent. They have been reported to be associated with a reduction in the incidence of early post-surgical infection rate after joint replacement and osteosynthesis.^{19–21}

The aim of this paper is to present the general technique at revision THA, including a description of our experience with the DAC hydrogel coating in patients undergoing 2 stage revision THA for PJI. We present the results in our first 28 cases with the use of this novel technology.

DAC technology and clinical experience

DAC hydrogel might be among the first antimicrobial coating designed specifically to protect implanted biomaterials in orthopedics and traumatology.^{19,22} It has proved to be safe and effective in reducing early post-surgical infection both in arthroplasties, osteosynthesis and revision surgery,^{21,23,24} as shown the inventing surgeons and research team. This gel is based on the ability of hyaluronic-based compounds to reduce bacterial adhesion and biofilm formation and to protect against various infectious agents.^{24–28}

In vitro, significant reductions of adhering bacteria on sterile titanium discs, coated with DAC hydrogel, were observed after 15, 30, 60, and 120 minutes of incubation.²² It was designed as a stand-alone product but has demonstrated the ability to elute antibiotics locally for up to 72 hours, in concentrations significantly higher than the minimum inhibitory concentration (MIC), in a time- and dose-dependent manner.¹⁹ Initial testing of effectiveness and safety was investigated in animal studies that showed the ability of the antibiotic-loaded hydrogel to prevent implant-related infection significantly with systemic antibiotic prophylaxis.²⁹ In addition it has been shown to have no impact on bone healing and implant osteointegration.³⁰

DAC was used in 28 patients who underwent elective uncemented two stage revision total hip arthroplasty. All patients had a confirmed chronic PJI, acute infection was not included. The presence of a PJI was confirmed by aspiration of the joint with subsequent microbiological analysis. PJI was diagnosed based on the MSIS criteria.

The preparation of DAC consists of a mixture of 300 mg of DAC, 5 mL of sterile (Figure 1) water and liquid based antibiotic according to the sensitivity of the organism previously identified in the cultures. It is possible to use more than one antibiotic. In our practice DAC was applied to the surface of the acetabular and the femoral components after approximately 10 minutes following mixing by directly spreading it on the surfaces of the implant (Figures 2 and 3). Bone preparation and prosthesis implantation then proceeded as per a normal uncemented prosthesis.

The average follow-up time was 24 months in our cohort.^{20–22,31} All cases were performed by a single surgeon, using a standard infection treatment protocol. All patients underwent careful debridement, removal of all previous hardware, pulsatile lavage; the team changed gloves, sterile disposable drapes and instruments used during debridement. Regarding to the type of fixation, non-cemented THR were used for acetabular and femoral fixation in all cases. All patients underwent a 2-stage revision including premanufactured cement spacer (Tecres, Italy). The interval between stages was 6–8 weeks (range 6.5 weeks). There were no antibiotic holidays and




Figure 2. Spreading the compost on the surface of cementless acetabular cup.

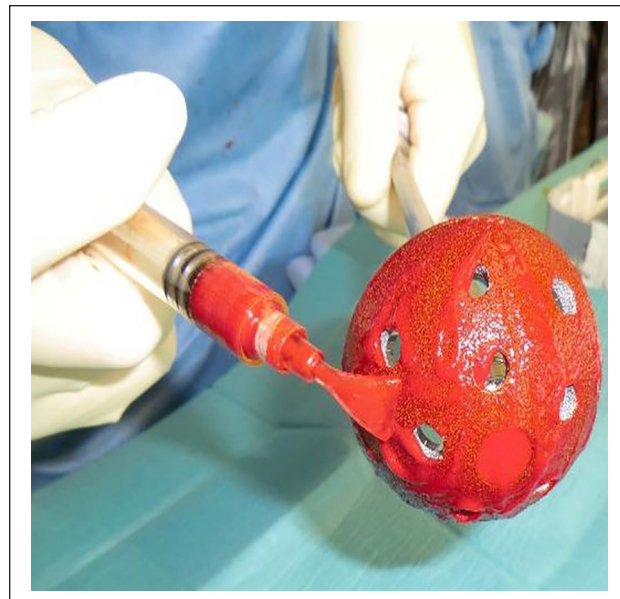

Figure 4. DAC with rifampicin on the surface of cementless acetabular.




Figure 3. Spreading the compost on the surface of cementless femoral stem.

no further aspiration between stages. Decision for re-implantation was based on clinical findings, including complete wound healing and C-reactive protein improvement. This was the case for all patients in our cohort.

Intraoperative technique

Although the DAC manufacturer allows mixing >1 antibiotic to the gel, based on patient specific germs, in our series only 1 antibiotic was used per patient. The 3 most often used local antibiotics in our series were: vancomycin, rifampicin or cephalosporin (Figures 4 and 5). All patients remained on intravenous antibiotics for 14 days and a further 6 weeks on orals.

Clinical results

The mean follow-up was 24 months (range 20–26 months). Out of our initial 28 THA cases, we have found 2 early failures/re-infections after the 2-staged protocol. Both occurred during the first 3 weeks after implantation. Both underwent revision with implant removal and re-implantation during the same procedure. All remaining 26 patients did not show clinical, laboratory signs of reinfection after last follow-up. In addition, we did not see any loosening or failure of ingrowth of the above mentioned uncemented implants.

Discussion

Antibacterial coatings still need to get a definite role in primary arthroplasties and in the treatment algorithms for PJIs.³² Even if some studies showed promising results, more data is needed to better understand their use in the orthopedic practice. Our first series shows promising results in terms of infection control and safety of use of DAC.

In the recent international Consensus meeting of 2018 on peri-prosthetic joint infections a strong recommendation was delivered, concerning the need for developing effective antibacterial surfaces that prevent bacterial adhesion and colonisation of implants and proliferation into the surrounding tissues. Thus, there is consensus that while antibiotic-loaded spacers appear to be safe.^{31,33}

The pathophysiological model for PJIs is a “race for the surface”, hence the first hours after the implant placement are crucial for the development of an infection.^{17,32,34} An antibiotic-loaded fast-resorbable hydrogel coating may

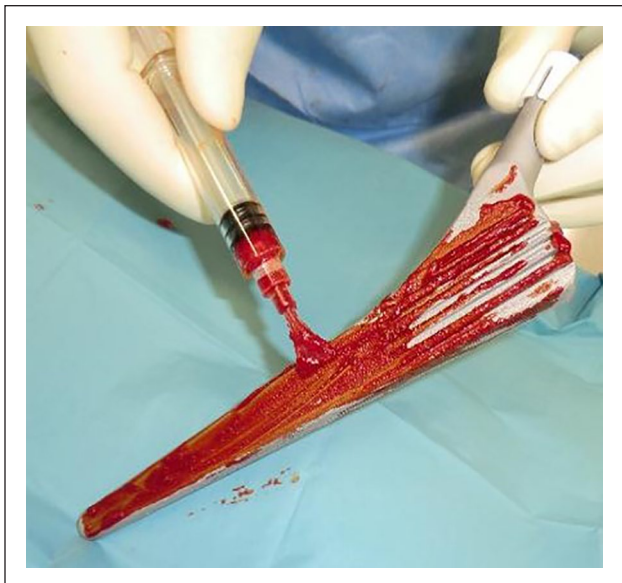


Figure 5. DAC with rifampicin.

offer ease of use, versatility and large scale applications, opening the way to an affordable wide application of antibacterial implant protection, as recently shown in a multi-center trial focused on infection prevention in total hip and knee replacement.²¹

Several technologies have been proposed to prevent early bacterial colonisation.^{21,35,36}

Burtscher et al.³⁷ compared *in vitro* biocompatibility and antimicrobial activity. The results showed good biocompatibility of all the metal-doped calcium-phosphate coatings, furthermore copper- and silver-doped layers showed significant antibacterial effects against *Staphylococcus aureus*.³⁷

Silver coating is probably the most studied on this regard. Wafa et al.³⁸ showed in a retrospective analysis that the use of silver-coated tumor prosthesis was effective in reducing early postoperative septic complications both in oncological patients and in two-stage revision for infection. Conversely, Zajonz et al.³⁹ reported only limited efficacy of silver-coated prosthesis in revision surgery for PJIs. Silver-coated implants also presents several limitations including silver cytotoxicity, impossibility to coat all the implant and high costs, limiting their extensive use.⁴⁰

Another possible attend for chronic bone infections is described by so called Bioactive Glass. Lindfors et al.⁴¹ showed that Bioactive Glass (BAG-S53P4) is a suitable as bone void filler in the treatment of chronic osteomyelitis; it is a bone substitute with proven antibacterial and bone bonding properties. Aurégan et al.⁴² in a systematically review of the results of 41 patients who underwent bioactive glass for long-bone infection in the clinical setting, showed good results, with only 3 recurrences of osteomyelites.⁴² However, this has not been adapted in the use of chronic PJI of the hip joint.

Obviously, there are some limitations in adapting the DAC technique to PJI treatment of the hip. First of all, the combination of this technique to cemented implants does not make sense. Furthermore, the total amount of adding topic antibiotics to the gel is limited, and there have been no studies to our knowledge showing the local bioactivity of the gel against infection *in vitro*.

Adding, critical remains the cost factor, which is roughly between 500 and 600 Euros in our set up for the use of one 10-ml gel syringe application.

A further indication of its use has been established in our clinic for 1-staged THA procedures. In contradiction of the classical described one-staged technique with cemented implants, we started a first clinical trial of a complete uncemented technique including tailored antibiotics added locally by the above described DAC technique. So far with promising results.

Conclusion

In agreement with other series, DAC was found to be effective in the treatment of PJI. The results obtained in ours first 28 cases were promising, with only 2 cases of recurrence in the early phase, and after all after final follow-up of 2 years, and the remaining 26 patients cured of their infections. More casuistry is necessary to consolidate DAC as a decisive factor in the treatment of PJI. Further indications are seen for its use at 1-staged procedure at chronic PJI.

Declaration of conflicting interests

The author(s) declared no potential conflicts of interest with respect to the research, authorship, and/or publication of this article.

Funding

The author(s) received no financial support for the research, authorship and/or publication of this article.

References

1. Parvizi J, Fassihi SC and Enayatollahi MA. Diagnosis of periprosthetic joint infection following hip and knee arthroplasty. *Orthop Clin North Am* 2016; 47: 505–515.
2. Maradit Kremers H, Larson DR, Crowson CS, et al. Prevalence of total hip and knee replacement in the United States. *J Bone Joint Surg Am* 2015; 97: 1386–1397.
3. Campos L. A perspective on the OECD report “Health at a Glance 2017”. *Acta Med Port* 2018; 31: 9–11.
4. Gundtoft PH, Pedersen AB, Varnum C, et al. Increased mortality after prosthetic joint infection in primary THA. *Clin Orthop Relat Res* 2017; 475: 2623–2631.
5. Lenguerand E, Pedersen AB, Varnum C, et al. Revision for prosthetic joint infection following hip arthroplasty: evidence from the national joint registry. *Bone Joint Res* 2017; 6: 391–398.
6. Springer BD, Cahue S, Etkin CD, et al. Infection burden in total hip and knee arthroplasties: an international registry-based perspective. *Arthroplast Today* 2017; 3: 137–140.

7. Haddad FS and George DA. Can national joint registries play a role in improving our understanding of periprosthetic infections? *Bone Joint J* 2016; 98-B: 289–290.
8. Gundtoft PH, Overgaard S, Schönheyder HC, et al. The “true” incidence of surgically treated deep prosthetic joint infection after 32,896 primary total hip arthroplasties: a prospective cohort study. *Acta Orthop* 2015; 86: 326–334.
9. Parvizi J, Shohat N and Gehrke T. Prevention of periprosthetic joint infection: new guidelines. *Bone Joint J* 2017; 99-B(Suppl. B): 3–10.
10. Gulland A. WHO launches global guidelines to stop surgical site infections. *BMJ* 2016; 355: i5942.
11. Gundtoft PH, Pedersen AB, Schönheyder HC, et al. Validation of the diagnosis ‘prosthetic joint infection’ in the Danish hip arthroplasty register. *Bone Joint J* 2016; 98-B: 320–325.
12. Kapadia BH, Berg RA, Daley JA, et al. Periprosthetic joint infection. *Lancet* 2016; 387: 386–394.
13. Brochin RL, Phan K, Poeran J, et al. Trends in periprosthetic hip infection and associated costs: a population-based study assessing the impact of hospital factors using national data. *J Arthroplasty* 2018; 33: S233–S238.
14. Kamath AF, Ong KL, Lau E, et al. Quantifying the burden of revision total joint arthroplasty for periprosthetic infection. *J Arthroplasty* 2015; 30: 1492–1497.
15. Vanhegan IS, Malik AK, Jayakumar P, et al. A financial analysis of revision hip arthroplasty: the economic burden in relation to the national tariff. *J Bone Joint Surg Br* 2012; 94: 619–623.
16. Klouche S, Sariali E and Mamoudy P. Total hip arthroplasty revision due to infection: a cost analysis approach. *Orthop Traumatol Surg Res* 2010; 96: 124–132.
17. Gristina AG, Naylor P and Myrvik Q. Infections from biomaterials and implants: a race for the surface. *Med Prog Technol* 1988; 14: 205–224.
18. Dastgheyb S, Parvizi J, Shapiro IM, et al. Effect of biofilms on recalcitrance of staphylococcal joint infection to antibiotic treatment. *J Infect Dis* 2015; 211: 641–650.
19. Drago L, Boot W, Dimas K, et al. Does implant coating with antibacterial-loaded hydrogel reduce bacterial colonization and biofilm formation in vitro? *Clin Orthop Relat Res* 2014; 472: 3311–3323.
20. Pitarresi G, Palumbo FS, Calascibetta F, et al. Medicated hydrogels of hyaluronic acid derivatives for use in orthopedic field. *Int J Pharm* 2013; 449: 84–94.
21. Romanò CL, Malizos K, Capuano N, et al. Does an antibiotic-loaded hydrogel coating reduce early post-surgical infection after joint arthroplasty? *J Bone Jt Infect* 2016; 1: 34–41.
22. Romanò CL, De Vecchi E, Bortolin M, et al. Hyaluronic acid and its composites as a local antimicrobial/antiadhesive barrier. *J Bone Jt Infect* 2017; 2: 63–72.
23. Zagra L, Gallazzi E, Romanò D, et al. Two-stage cementless hip revision for peri-prosthetic infection with an antibacterial hydrogel coating: results of a comparative series. *Int Orthop* 2019; 43: 111–115.
24. Zagra L, Villa F, Cappelletti L, et al. Can leucocyte esterase replace frozen sections in the intraoperative diagnosis of prosthetic hip infection? *Bone Joint J* 2019; 101-B: 372–377.
25. Pavesio A, Renier D, Cassinelli C, et al. Anti-adhesive surfaces through hyaluronan coatings. *Med Device Technol* 1997; 8: 20–21, 24–27.
26. Cassinelli C, Morra M, Pavesio A, et al. Evaluation of interfacial properties of hyaluronan coated poly(methyl methacrylate) intraocular lenses. *J Biomater Sci Polym Ed* 2000; 11: 961–977.
27. Kadry AA, Fouda SI, Shibl AM, et al. Impact of slime dispersants and anti-adhesives on in vitro biofilm formation of *Staphylococcus epidermidis* on intraocular lenses and on antibiotic activities. *J Antimicrob Chemother* 2009; 63: 480–484.
28. Junter GA, Thébault P and Lebrun L. Polysaccharide-based antibiofilm surfaces. *Acta Biomater* 2016; 30: 13–25.
29. Giavaresi G, Meani E, Sartori M, et al. Efficacy of antibacterial-loaded coating in an in vivo model of acutely highly contaminated implant. *Int Orthop* 2014; 38: 1505–1512.
30. Boot W, Gawlitta D, Nikkels PGJ, et al. Hyaluronic acid-based hydrogel coating does not affect bone apposition at the implant surface in a rabbit model. *Clin Orthop Relat Res* 2017; 475: 1911–1919.
31. Cats-Baril W, Gehrke T, Huff K, et al. International consensus on periprosthetic joint infection: description of the consensus process. *Clin Orthop Relat Res* 2013; 471: 4065–4075.
32. Foster TJ, Geoghegan JA, Ganesh VK, et al. Adhesion, invasion and evasion: the many functions of the surface proteins of *Staphylococcus aureus*. *Nat Rev Microbiol* 2014; 12: 49–62.
33. Schwarz EM, Parvizi J, Gehrke T, et al. 2018 international consensus meeting on musculoskeletal infection: research priorities from the general assembly questions. *J Orthop Res* 2019; 37: 997–1006.
34. Costerton JW, Stewart PS and Greenberg EP. Bacterial biofilms: a common cause of persistent infections. *Science* 1999; 284: 1318–1322.
35. Romanò CL, Tsuchiya H, Morelli I, et al. Antibacterial coating of implants: are we missing something? *Bone Joint Res* 2019; 8: 199–206.
36. Folsch C, Federmann M, Kuehn KD, et al. Coating with a novel gentamicinpalmitate formulation prevents implant-associated osteomyelitis induced by methicillin-susceptible *Staphylococcus aureus* in a rat model. *Int Orthop* 2015; 39: 981–988.
37. Burtcher S, Krieg P, Killinger A, et al. Thin degradable coatings for optimization of osteointegration associated with simultaneous infection prophylaxis. *Materials (Basel)* 2019; 12: pii: E3495.
38. Wafa H, Grimer RJ, Reddy K, et al. Retrospective evaluation of the incidence of early periprosthetic infection with silver-treated endoprostheses in high-risk patients: case-control study. *Bone Joint J* 2015; 97-B: 252–257.
39. Zajonz D, Birke U, Ghanem M, et al. Silver-coated modular Megaendoprostheses in salvage revision arthroplasty after periimplant infection with extensive bone loss - a pilot study of 34 patients. *BMC Musculoskelet Disord* 2017; 18: 383.
40. Mijnenonckx K, Leys N, Mahillon J, et al. Antimicrobial silver: uses, toxicity and potential for resistance. *Biomaterials* 2013; 26: 609–621.
41. Lindfors N, Geurts J, Drago L, et al. Antibacterial bioactive glass, S53P4, for chronic bone infections - a multinational study. *Adv Exp Med Biol* 2017; 971: 81–92.
42. Aurégan JC and Bégué T. Bioactive glass for long bone infection: a systematic review. *Injury* 2015; 46(Suppl. 8): S3–S7.